



CASE REPORT

Two Case Reports of Actinomycosis: The Mysterious Ray Fungi with Spurious Clinical Diagnosis

¹VT Beena, ²Revathy K, ³Latha M Cherian, ⁴Indu M, ⁵Rishal Mohammed, ⁶Remya K

ABSTRACT

Introduction: Actinomycosis is an infectious disease that frequently has chronic granulomatous and suppurative lesions. It is caused by saprophytic *Actinomyces* species. This disease has been listed as a rare disease by the Office of Rare Disease at the National Institute of Health.

Case report: Here we report two cases involving the oral cavity of two middle-aged which the first patient was previously diagnosed as mucormycosis and was under antifungal treatment and the second case was sent with a provisional diagnosis of osteomyelitis, maxilla. In both the cases, the diagnosis was made as actinomycosis based on the case, clinical nature of the lesion, staining with Gomori's Methenamine Silver staining.

Management: A high dose of antibiotic therapy was given to both patients.

Conclusion: Due to the opportunistic nature of the actinomycotic infection, early and sufficient differential diagnosis of actinomycosis prior to therapeutic attempts are of great importance in the oral cavity to prevent the spread of the disease. These case of biopsy of any lesions that do not respond to conventional treatment modalities or those showing recurrence after the same.

Keywords: Actinomycosis, Bacteria, Oral cavity, Osteomyelitis, Ray fungus.

How to cite this article: Beena VT, Revathy K, Cherian LM, Indu M, Mohammed R, Remya K. Two Case Reports of Actinomycosis: The Mysterious Ray Fungi with Spurious Clinical Diagnosis. *Oral Maxillofac Pathol J* 2019;10(1):25-29.

Source of support: Nil

Conflict of interest: None

INTRODUCTION

Actinomycosis is an unusual saprophytic infection that is categorized by granulomatous and suppurative lesions

caused by common oral microbe, *Actinomyces israelii*.¹ It primarily affects soft tissues; osseous involvement occurs rarely. Actinomycotic osteomyelitis of maxilla is relatively rare when compared to the mandible, probably because of better circulation in maxilla which provides increased oxygen supply.

As suggested by Cope² in 1938 the infection may be classified anatomically as cervicofacial, thoracic or abdominal. The most common is cervicofacial, which accounts for over half of the reported cases.³

The microbiological picture reveals that this Gram-positive bacterium is non-acid fast, non-spore forming anaerobic, and microaerophilic with filamentous branching and lives as a commensal in the human body but acts aggressively when it invades the mucosal barrier and enters the subcutaneous tissue. This infection is extremely unusual in the oral mucosal membranes; when present, patients exhibit classical symptoms of abscesses, sinus tract formation, and woody fibrosis.⁴ The literature indicates that cervicofacial actinomycosis (CA) manifests after a traumatic event that affects the integrity of the barrier afforded by the oral mucosa, such as periodontal disease, tooth extraction, or any other form of surgical intervention. The occurrence of microtrauma enables the invasion of tissues by bacteria since the anaerobic environment favors the growth of these microorganisms and the establishment of an infectious process.⁵

CASE REPORTS

Case I

A 66-year-old male patient reported with pain and swelling on the right side of his edentulous upper jaw. He gave a past dental history of extraction 2 months back. Medical history revealed that he was diabetic. On extraoral examination, there was no facial asymmetry or swelling. Following the intraoral examination, the case was referred to oral surgery as it showed an intraoral bony hard swelling of his right alveolus and multiple areas of necrotic bone (Fig. 1A).

A biopsy was performed and a provisional diagnosis of osteomyelitis maxilla was given. On gross examination, a black bit of necrotic bone of size 2.5 cm × 1.5 cm × 0.5 cm with an irregular surface and which was gritty in consistency was obtained (Fig. 1B).

¹Principal and Professor, ^{2,5}Junior Resident, ³Professor and Head, ⁴Assistant Professor, ⁶Senior Resident

¹Government Dental College Kottayam, Kerala, India

²⁻⁵Department of Oral Pathology, Government Dental College Kottayam, Kerala, India

⁶Department of Oral Pathology, Government Dental College Thrissur, Kerala, India

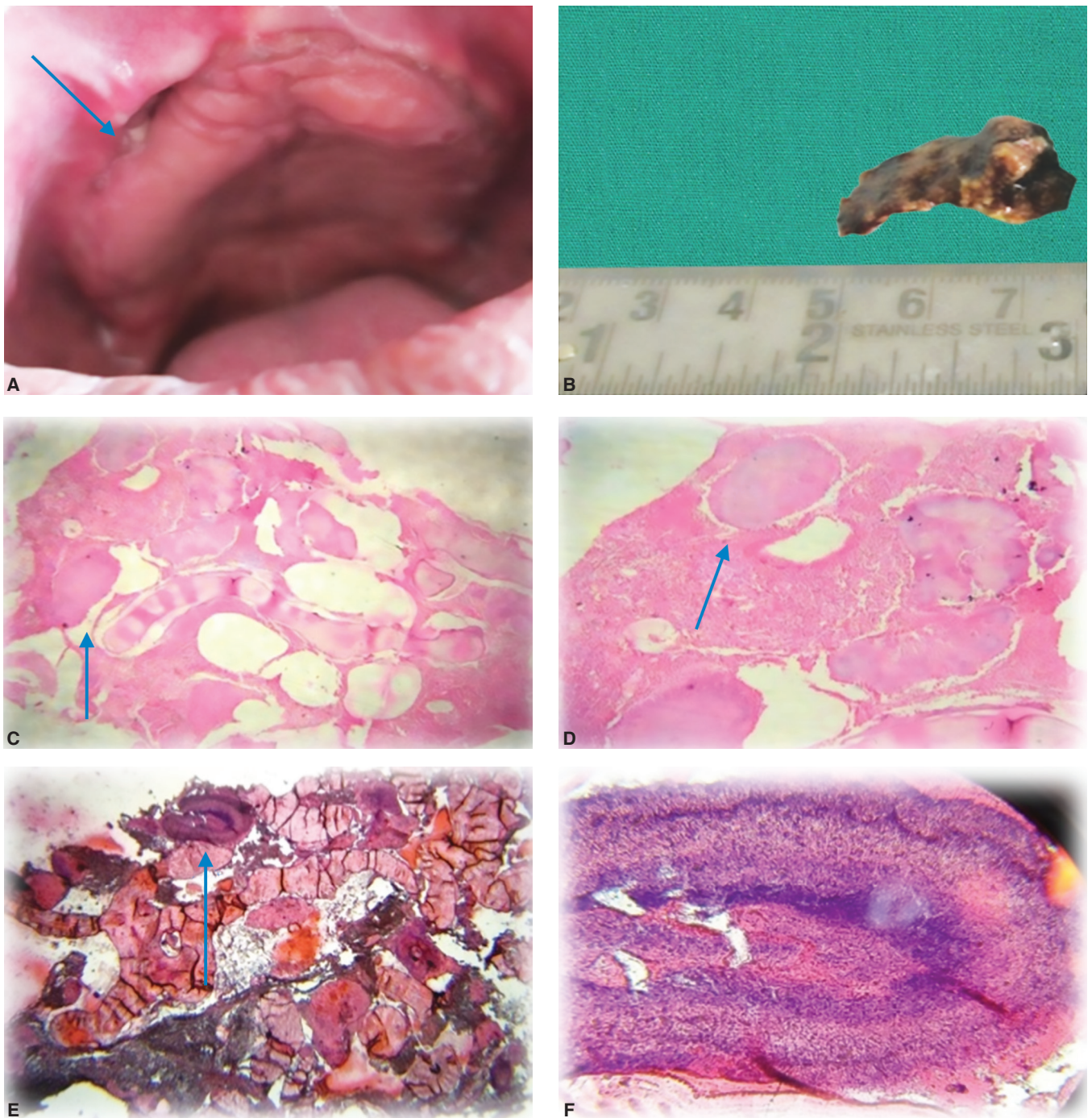
Corresponding author: Revathy K, Junior Residents, Department of Oral Pathology, Government Dental College Kottayam, Kerala, India, e-mail: revz2409@gmail.com

Routine H and E staining revealed areas of necrotic bony trabeculae showing filamentous radiating colonies with central basophilic areas and peripheral club-shaped eosinophilic filaments in marrow spaces (Figs 1C and D). To confirm the diagnosis special staining with Gomori's methenamine silver stain and Gram's stain was done. GMS stain showed dark colonies of filamentous radiating bacteria in a light green background of necrotic bony trabeculae (Figs 1E and F). Gram's stain revealed peripheral eosinophilic club-shaped filaments with central basophilic areas (Figs 1G and H).

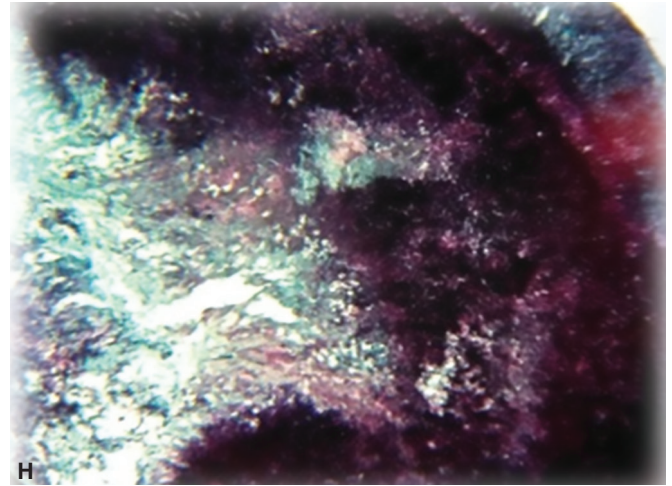
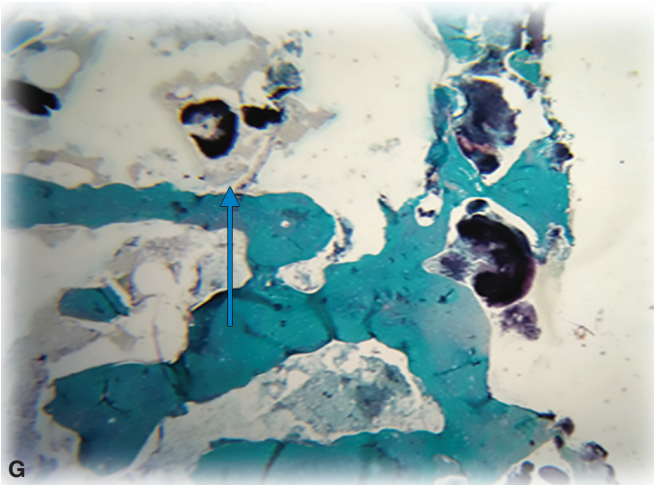
Based on this a diagnosis of actinomycotic osteomyelitis was given. The patient was put on a high dose of penicillin for 2 weeks. He was kept under regular follow up and showed a resolving lesion.

Case II

The second case was that of a 54-years-old male who reported with a chief complaint of an unresolved lesion of the right buccal vestibule. He was diagnosed as a case of mucormycosis elsewhere and was under antifungal therapy. As the lesion did not resolve he was referred



Figs 1A to F: (A) Necrotic lesion of the right buccal vestibule. (B) gross specimen; (C) H and E staining (4X); (D) H and E staining (10X); (E) Gram's stain (4X); (F) Gram's stain (40X)

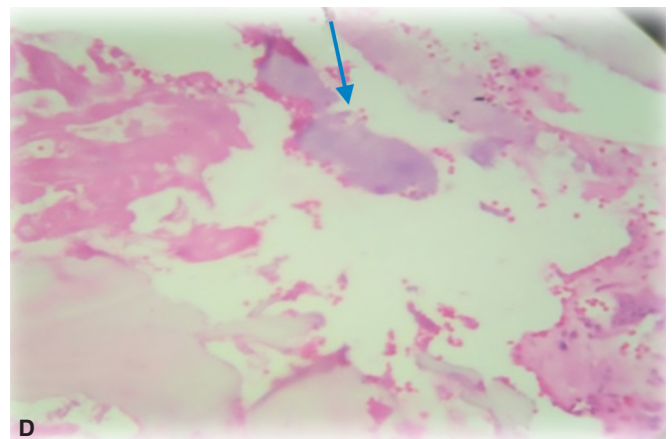
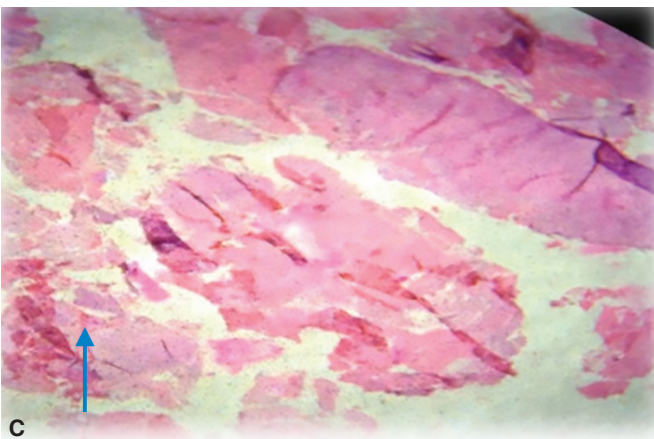
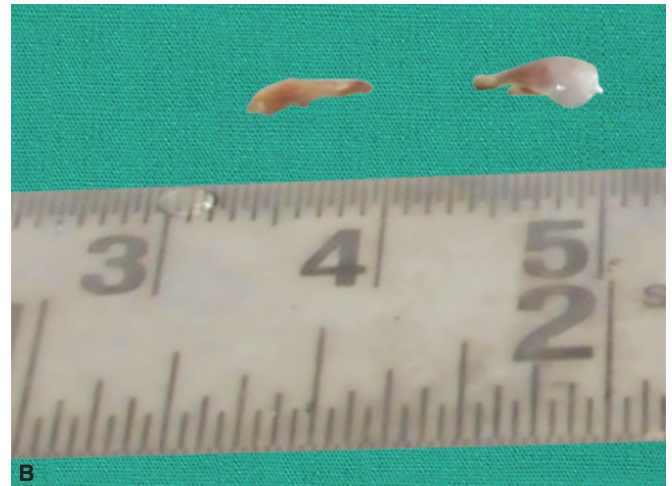
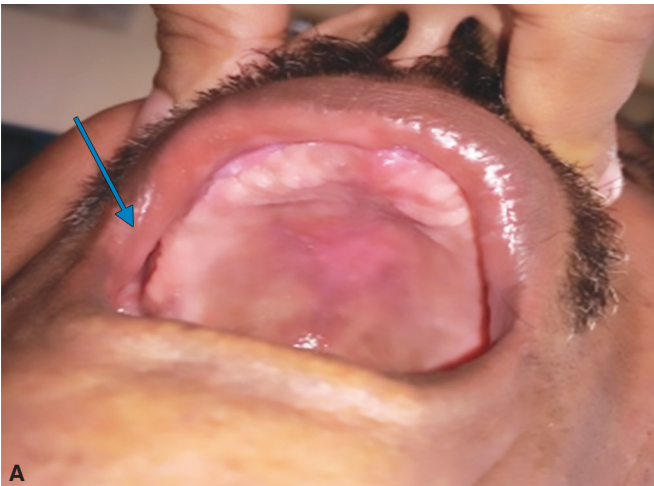

Figs 1G and H: (G) GMS stain (4X); (H) GMS stain (40X)

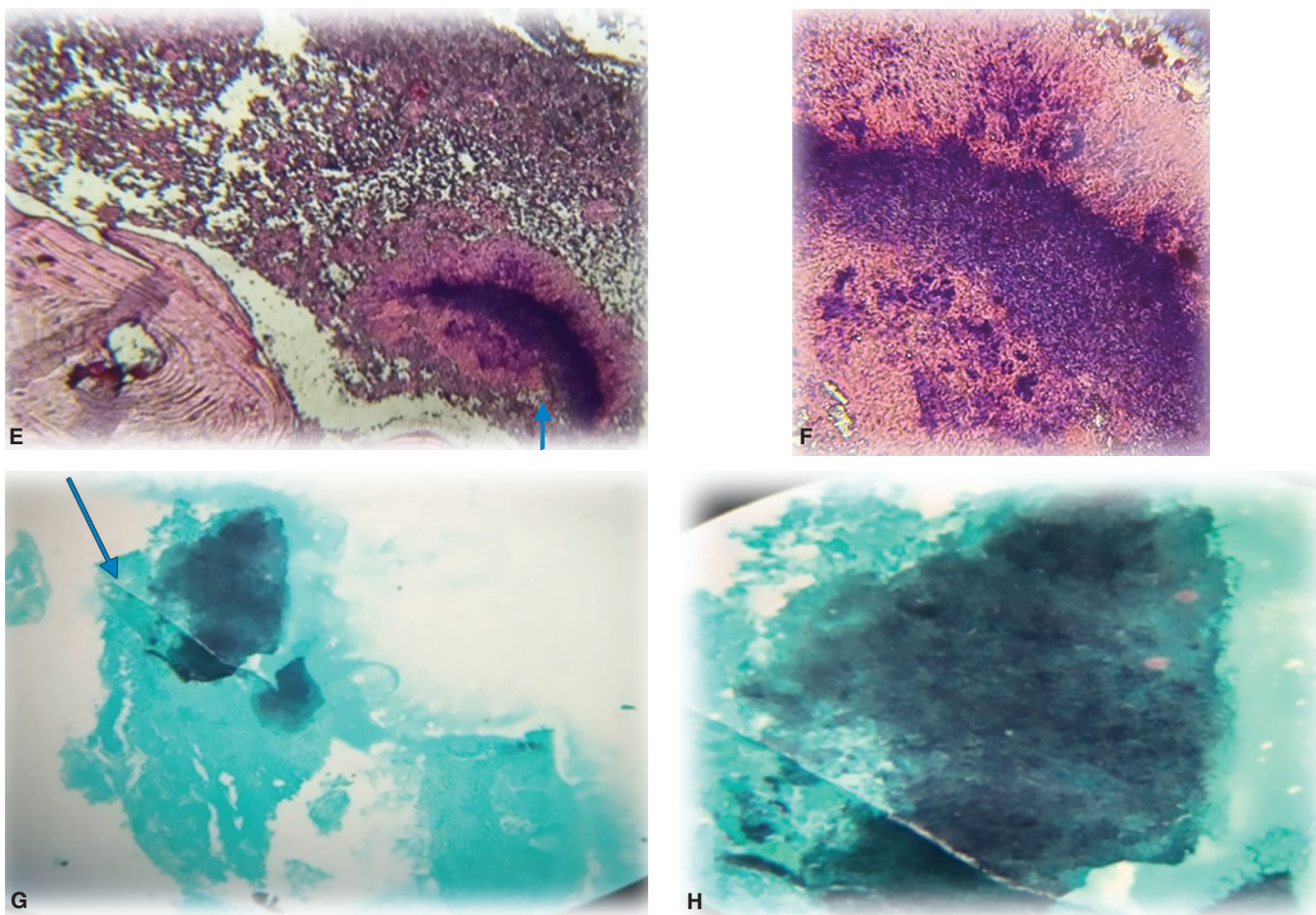
to our institution for a rebiopsy a few months later. On examination, he had an edentulous maxilla with his right maxillary sinus showing mucous filling perforating to his right buccal vestibule (Fig. 2A). An incision biopsy of the lesion was performed and sent for histopathological examination.

On gross examination, a dirty white soft tissue bit with a smooth surface of size 0.8 cm × 0.3 cm × 0.2 cm which was soft in consistency was obtained (Fig. 2B).

On histopathological examination, H and E serial sections of soft tissue bits with focal areas of pseudostratified ciliated columnar epithelium and presence of club-shaped filamentous colonies with central basophilic staining in the stroma was noted. Stroma also showed areas of necrosis, endothelial proliferation, and extravasated RBCs (Figs 2C and D). GMS stain showed dark colonies of filamentous radiating bacteria in a light green background of necrotic bony trabeculae. Gram's



Figs 2A to D: (A) Ulcerative lesion of the right buccal vestibule; (B) Gross specimen; (C) H and E staining (4X); (D) H and E staining (10X)



Figs 2E to H: (E) Gram's stain (10X); (F) Gram's stain (40X); (G) GMS stain (10X); (H) GMS stain (40X)

stain revealed peripheral eosinophilic club-shaped thin filaments with central basophilic areas unlike the thick filamentous molds of mucormycosis (Figs 2E and F).

Based on the findings a diagnosis of actinomycosis was given. The treatment of modality was changed from antifungal therapy to high dose Penicillin (Figs 2G and H).

DISCUSSION

Actinomyces species are non-acid fast, anaerobic micro-aerophilic bacteria showing filamentous branching. Actinomycosis is an extremely rare infection in the oral mucosal membranes and when present, patients exhibit classical symptoms of abscesses, sinus tract formation, and woody fibrosis.⁴ It affects predominantly males within the age group of 4th to 6th decades of life.⁶

Disruption of the mucosal barrier is the main triggering factor of the infection.⁷ The first case report shows infection following extraction of his upper teeth.

Cervicofacial actinomycosis takes on a variety of clinical manifestations, whether chronic or acute and affects mainly the mandible.⁸ Actinomycosis of the maxilla accounts for only 0.5-9% of all head and neck cases. There are only a few cases reported in the literature of primary

actinomycosis arising within the maxilla. Here both the cases affected the maxilla.

Systemic aspects such as diabetes can lead to the progress of the disease. Sulfur granules are considered to be indicative of actinomycotic infection.⁹ It is well-known that pathological investigation is crucial in the diagnosis of actinomycosis since it can reveal an outer area of granulation tissue and an inner area of necrosis that contains colonies of *Actinomyces* on microscopic examination. The microscopic round to oval lobulated basophilic structures surrounded by eosinophilic material producing a club-shaped appearance (termed the Splendore-Hoeppli phenomenon) suggested actinomycosis.⁴

A Gram stain of the specimen is usually more sensitive than culture, especially if the patient has received antibiotics. *Actinomyces* are non-spore-forming Gram-positive rods. Gomoris methenamine silver stain best demonstrates the organisms as black colonies in a light green background.

Oral actinomycosis manifesting with sinus tract formation should be differentiated from other etiologies, including tuberculosis, mucormycosis and coccidioides, nocardiosis and neoplasm.⁶ In the second case, the possibility of mucormycosis had to be ruled

out. Mucormycosis, unlike actinomycosis, shows large nonseptate hyphae at the periphery with branching at 90°. Also fungal hyphae are of larger size with an average of 6 to 30 µm.¹⁰ Thus the previous diagnosis of mucormycosis could be ruled out as the colonies did not exhibit the above features. The treatment regimen for mucormycosis was discontinued and changed from antifungal to Penicillin. But the patient did not turn up for follow-up.

A diagnosis of actinomycosis is best made by culture, but <50% of cases are positive due to numerous problems associated with culturing these organisms.¹¹ Both the patients were treated with oral penicillin, which is the drug of choice. The treatment was planned to be continued for at least 6 months. Generally, serious infection and bulky disease should be treated with intravenous penicillin for 2 to 6 weeks followed by oral penicillin for 12 months, and low bulk oral disease can be treated with oral agents for a shorter period.

CONCLUSION

This case series reported highlights the importance of histopathological diagnosis in routine clinical practice. The possibility of actinomycosis was not even considered by the clinicians in both cases. When the diagnosis is missed, definitive treatment cannot be provided which can lead to substantial morbidity and mortality. Biopsies of such lesions are mandatory for a definitive diagnosis and prognosis of the lesion. High dose Penicillin for a period of 6 months is now given as the standard regimen for actinomycotic infections.

Thus clinicians should be aware of the possibility of actinomycosis of the maxilla, though rare and the importance of biopsy in arriving at a definitive and timely diagnosis.

REFERENCES

1. Klein M, Carrard VC, Munerato MC .Cervicofacial Actinomycosis of the Maxilla and HIV Infection: A Case Report. *Otolaryngol (Sunnyvale)*.2017; 7: 288.
2. Cope, Z. *Actinomycosis*. Oxford University Press, London.1938;71-77
3. Belmont M J, Behar P M, Wax M K. Atypical presentations of actinomycosis. *Head Neck* 1999; 21: 264-268.
4. Thukral R, Shrivastav K, Mathur V, Barodiya A, Shrivastav S. Actinomyces: a deceptive infection of oral cavity. *Journal of the Korean Association of Oral and Maxillofacial Surgeons*. 2017;43(4):282-285. doi:10.5125/jkaoms.2017.43.4.282.
5. Schmidt T, Caselli G, Díaz R Actinomicosis del huesomaxilar superior. *Rev Otorrinolaringol Cir Cabeza Cuello*.2003; 63: 127-131.
6. M. Miller, A.J. Haddad, Cervicofacial actinomycosis, *Oral Surg. Oral Med. Oral Pathol. Oral Radiol. Endod*.1998;85(5): 496–508.
7. Crossman T, Herold J. Actinomycosis of the maxilla-a case report of a rare oral infection presenting in general dental practice. *Br Dent J* 2009;206(4):201-202.
8. Yadegarynia D, Merza MA, Sali S, Firuzkuhi AG. A rare case presentation of oral actinomycosis. *Int J Mycobacteriol* 2013;2:187-189
9. Rajendran R, Sivapathasundharam B. *Shafer's Text Book of Oral Pathology*.2006; 318-320.
10. Neville B, Damm D, Allen C, Bouquot J. *Oral and maxillofacial Pathology*. 3rd ed. Philadelphia. Saunders: An imprint of Elsevier Inc; 1998.
11. Rush JR, Sulte HR, Cohen DM, Makkawy H. Course of infection and case outcome in individuals diagnosed with microbial colonies morphologically consistent with Actinomyces species. *J Endod* 2002;28:613e8.